Anaesthesia Consideration in lung resection

Presenter : Dr Surbhi
Moderator:Dr Bhupinder

Lung Resection and Types

- Pneumonectomy
- Lobectomy
- Sleeve lobectomy
- Wedge resection
- Segment resection

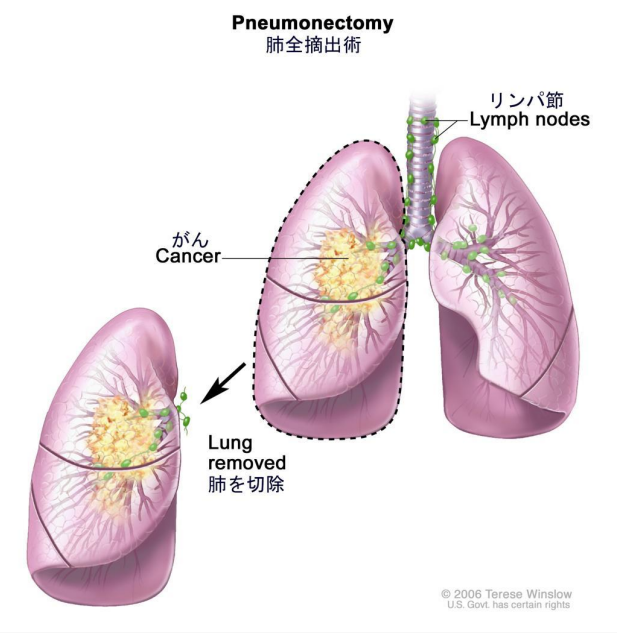
Pneumonectomy
肺全摘出術
リンパ節
Lymph nodes
がん
Cancer
Lung
removed
肺を切除
© 2006 Terese Winslow
U.S. Govt. has certain rights

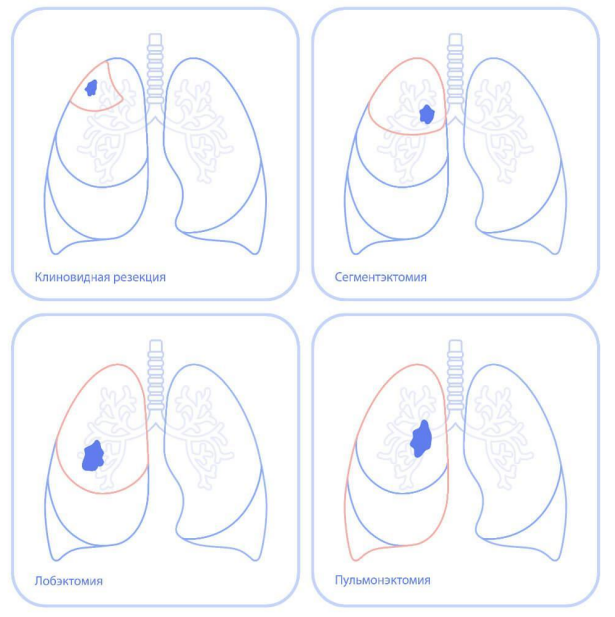
Клиновидная резекция
Сегментэктомия
Лобэктомия
Пульмонэктомия

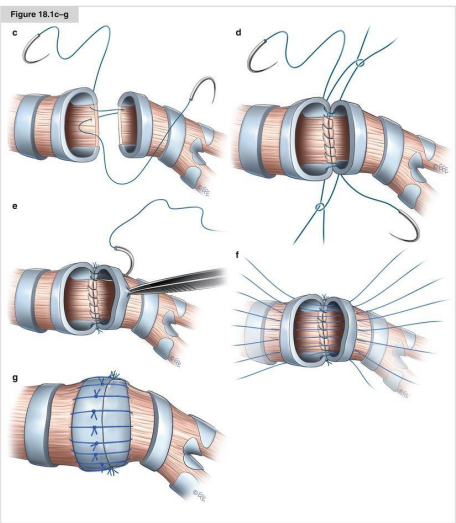
Figure 18.1c–g
c
d
e
f
g

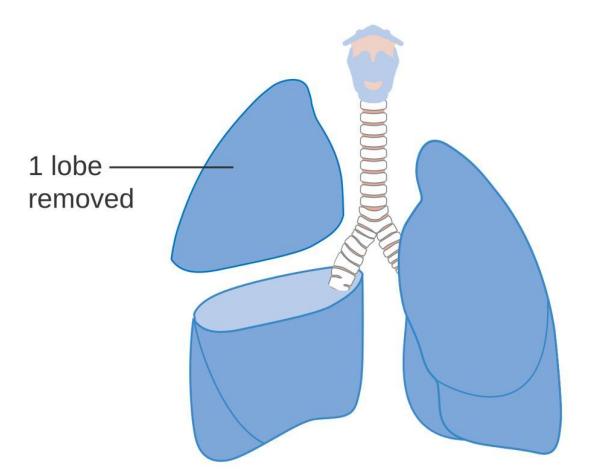
1 lobe
removed

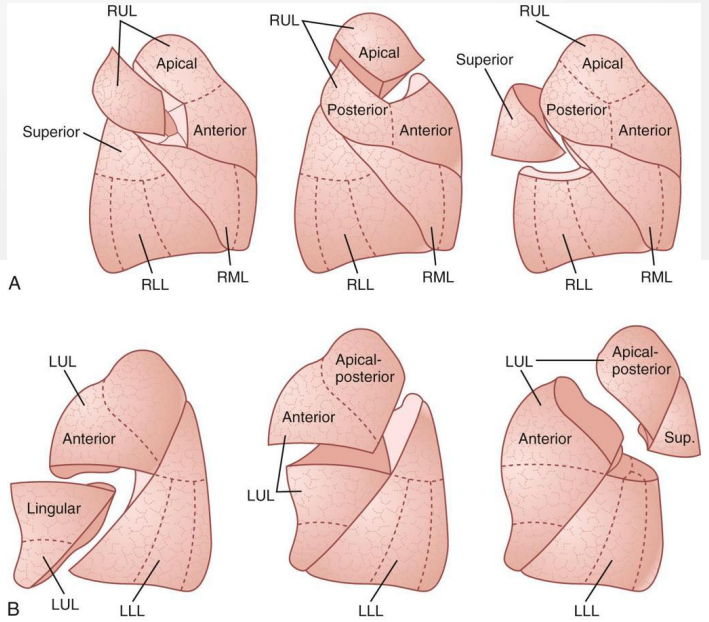
RUL
Apical
Superior
Anterior
RLL
RML
A
RUL
Apical
Posterior
Anterior
RLL
RML
RUL
Superior
Apical
Posterior
Anterior
RLL
RML
LUL
Anterior
Lingular
B
LUL
LLL
Apical-
posterior
Anterior
LUL
LLL
LUL
Apical-
posterior
Anterior
Sup.
LLL

History:

- age
- Dyspnea and cough
- Smoking - duration & frequency
- exposure to asbestos or radiation
- Chest pain
- Recent infections
- Immobility
- metastatic disease-Mass effects and metabolic effects of lung cancers.
- Current medications

Anesthesia for Pneumonectomy

- Pre operative assessment
- Pre operative preparation
- Intraoperative management→
- Induction & maintenance Monitoring
- Positioning
- lung isolation techniques
- one lung ventilation
- Post op analgesia
- Complications

Preoperative Thoracic Revised Cardiac Risk Index (TRCRI)

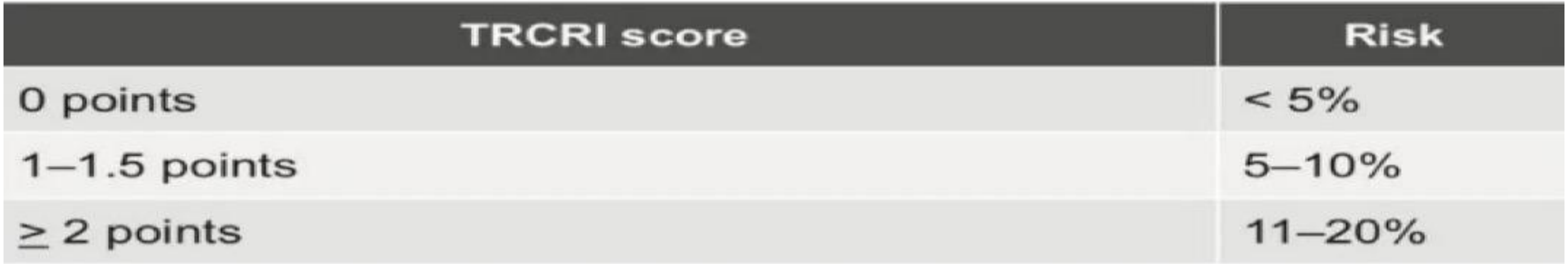

TRCRI score	Risk
0 points	< 5%
1–1.5 points	5–10%
≥ 2 points	11–20%

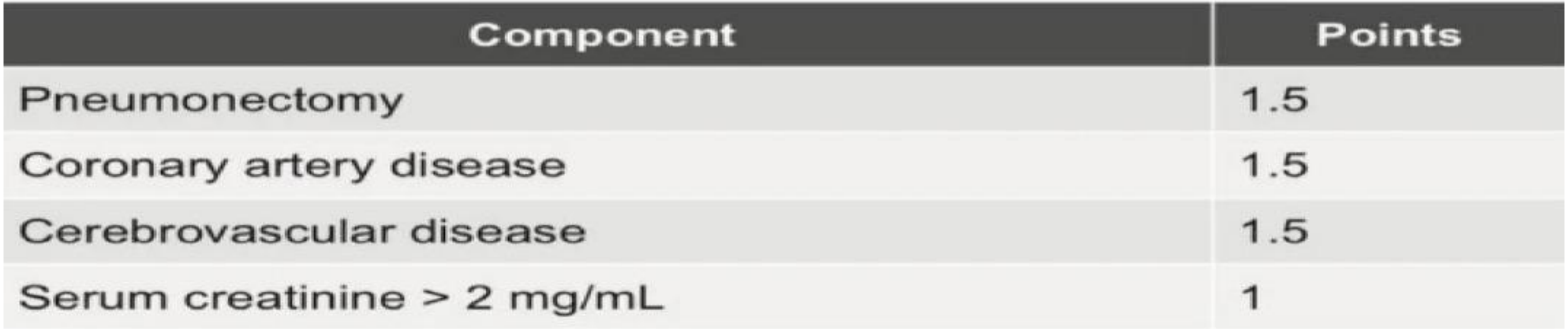

Component	Points
Pneumonectomy	1.5
Coronary artery disease	1.5
Cerebrovascular disease	1.5
Serum creatinine > 2 mg/mL	1

Investigations

- Complete Blood Count
- Sputum Culture And Sensitivity -To Guide Appropriate Antibiotic Therapy
- PT/INR ,LFT , RFT ,Viral Markers , blood grouping
- Chest X Ray
- ECG
- Echocardiography
- Pulmonary Function Tests

Any Further Investigations:

- Patients with a preoperative FEV, and DLCO that are both **≥80 percent** predicted do not need to undergo further testing for assessing postoperative lung function or risk.
- Preoperative FEV1 and DLCO **<80 percent** predicted need to undergo further evaluation to allow calculation of **predicted postoperative (PPO) lung function**

- Most valid single test for post thoracotomy respiratory complications is the predictive postoperative FEV1 {ppo FEV1%} which is calculated as

$$\text{ppoFEV1\%} = \text{preop FEV1\%} \times (1 - \text{\%Functional lung tissue removed}/100)$$

Ppo FEV1

- >40% -Low risk
- 30-40%- mod risk
- < 30% - high risk

Algorithm for preop respiratory evaluation for pulmonary resection



Functional capacity >2 METS

SPIROMETRY:
ppoFEV1 and ppoDLCO

BOTH > 60%

EITHER 60%-30

EITHER <30%

Simple exercise testing

6MWT>400M

6MWT<400M

**Cardiopulmonary
Exercise testing**

VO2max
>10ml/kg/min

VO2max
<10ml/kg/min

Functional capacity < 2MET

Defer for medical consultation
and optimisation

**Proceed with scheduled
Pulmonary Resection**

**Increased risk for scheduled
pulmonary resection**

**High Risk
Consider alternative therapies**

Preoperative Optimization

- Cessation of smoking
- Preoperative Nebulisation
- Mucolytic and expectorant drugs
- Chest physiotherapy
- Stabilize other medical problems
- Medication Antibiotics-if purulent sputum
- Preoperative Incentive spirometry
- Deep breathing exercises

General Anaesthesia:-

- Rapid sequence induction is better to reduce aspiration risk.
- Premedication
- Opioids for Analgesia
- Intravenous induction: propofol, thiopental or etomidate
- Rapidly acting NMB such as succinylcholine or rocuronium.
- Intubation: appropriate size of DLT /Bronchial blocker for lung isolation and maintain OLV

Maintenance of Anesthesia:

- Balanced anesthesia with 0.5 -1 MAC isoflurane or sevoflurane
- TIVA may be advantageous as volatile anesthetics inhibit HPV
- Intermittent boluses of fentanyl - analgesia
- Intermediate acting NMBAs - to maintain neuromuscular paralysis

Intraoperative Monitoring

- ECG
- Non invasive Blood Pressure
- Pulse Oximetry
- Capnography
- Invasive Arterial blood pressure
- Fiberoptic bronchoscopy
- Urine output
- Temperature

OPTIONS FOR LUNG ISOLATION

Double Lumen Tubes

(MOST COMMON)

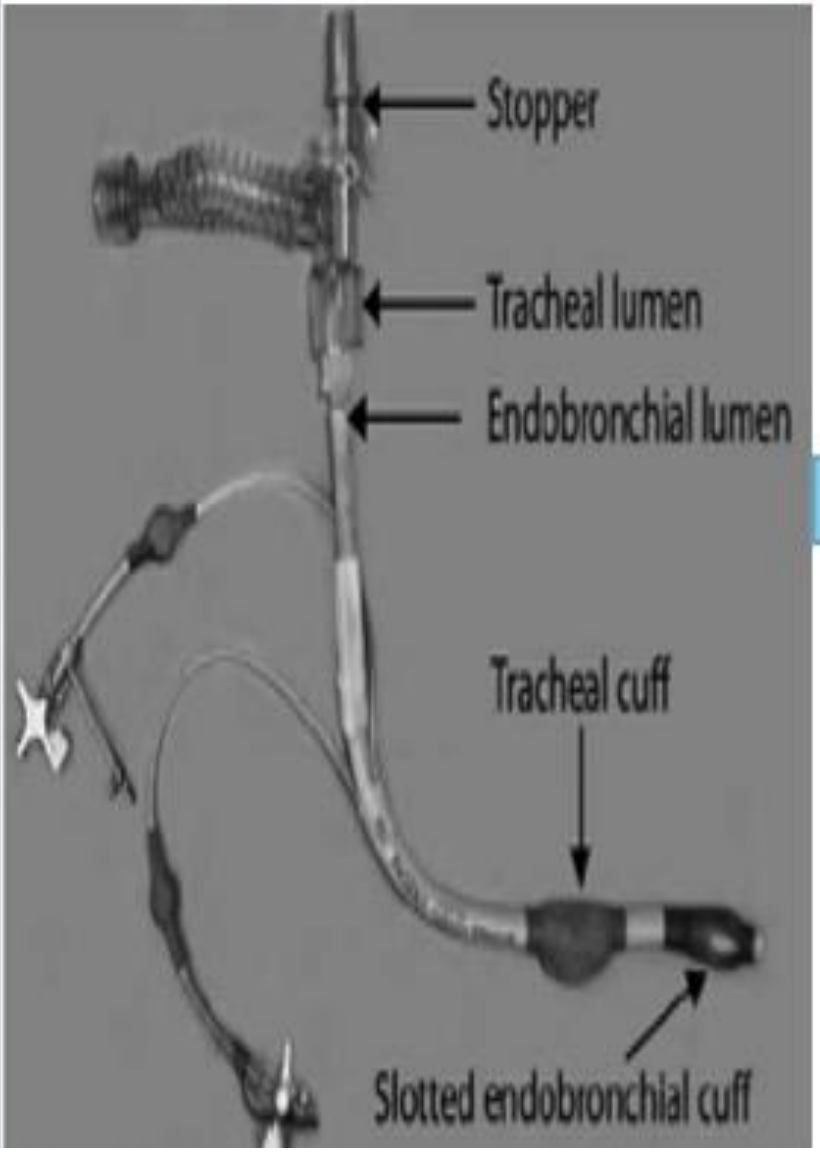
Stopper
Tracheal lumen
Endobronchial lumen
Tracheal cuff
Slotted endobronchial cuff

DLT:

- Bifurcated tube with both endotracheal and endobronchial lumen
- To achieve isolation of either right or left lung

Bronchial Blockers

Blockade of main stem bronchus to allow lung collapse distal to occlusion

Single Lumen Tubes

(RARELY USED)

Offers limited access to non ventilated lung and is difficulty to position.

DLT

- Most commonly used
- DLT allows for ventilation of both bronchial lumens through a single circuit.
- SLT ☾ designed to terminate above the carina ☾ distal portion of a DLT is angled to fit into the appropriate mainstem bronchus.
- Has two cuffs ☾ tracheal and bronchial cuffs ☾ require approx 6-8 ml and 1-3 ml of air.

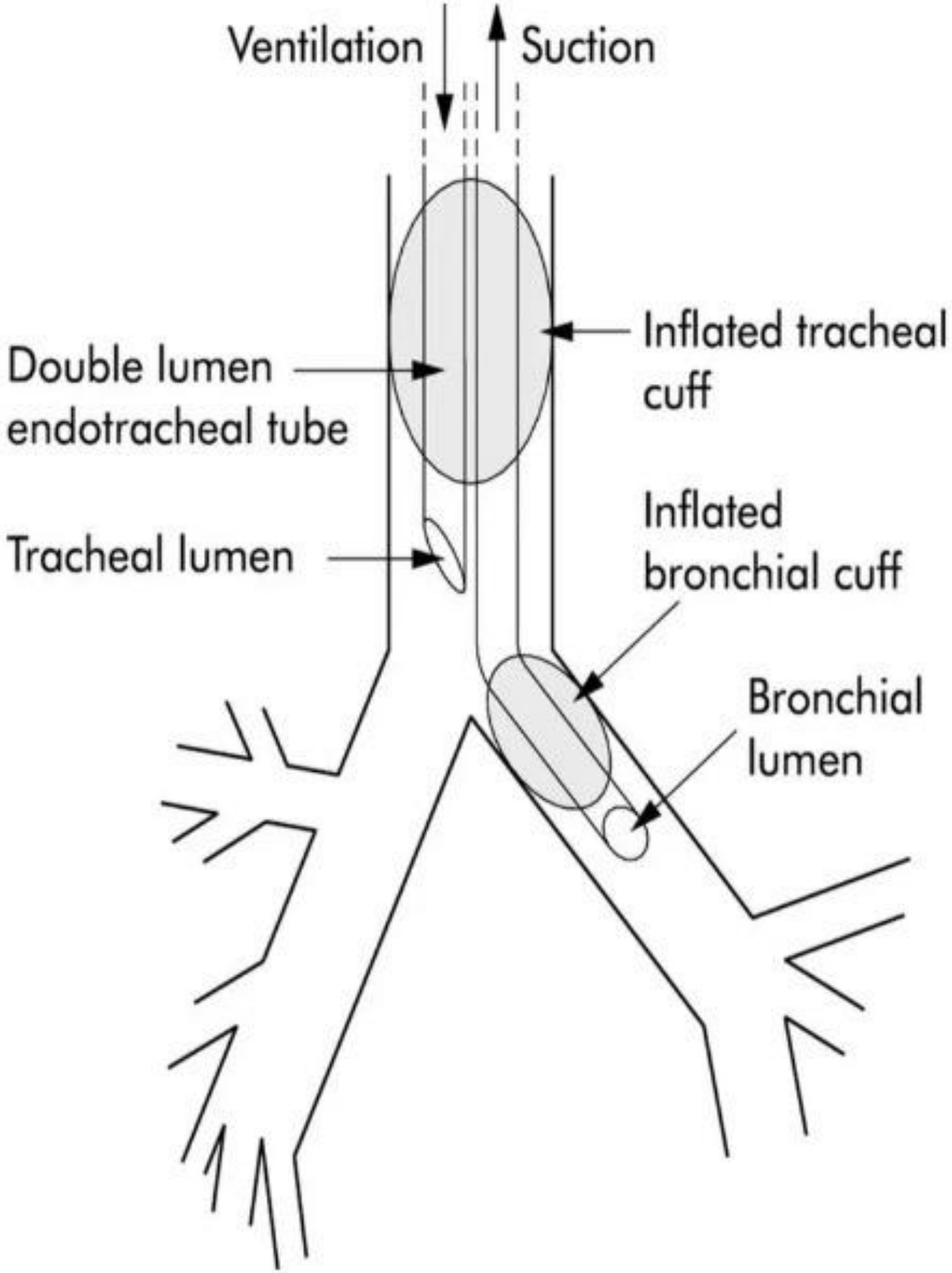
Ventilation
Suction
Inflated tracheal cuff
Double lumen endotracheal tube
Tracheal lumen
Inflated bronchial cuff
Bronchial lumen

Types of DLT

NAME	BRONCHUS INTUBATED	CARINAL HOOK	SHAPE OF LUMEN
Carlens	Left	Yes	Oval
White	Right	Yes	Oval
Robert-shaw	Right or left	No	D-shaped
Bryce-smith	Left	No	Oval
Bryce-smith-salt	Right	No	Oval

Robertshaw


White

Carlens

- Most commonly used DLT is Robert Shaw type

- Size selection:

Male	>170cm	41 fr
	<170 cm	39fr
Female	>160cm	37fr
	<160cm	35fr

Depth of insertion: 12 + pt. height/10 cm

Method Of Insertion

- Blind technique:
  - DLT is passed with direct laryngoscopy
  - Turn 90 ° left (for left-sided DLT) after the endobronchial cuff has passed beyond the vocal cords.
  - The DLT should pass the glottis without any resistance.

- Bronchoscopic guidance
  - Tip of the endobronchial lumen is guided into the correct bronchus after the DLT passes the vocal cords using direct vision with a flexible fiberoptic bronchoscope

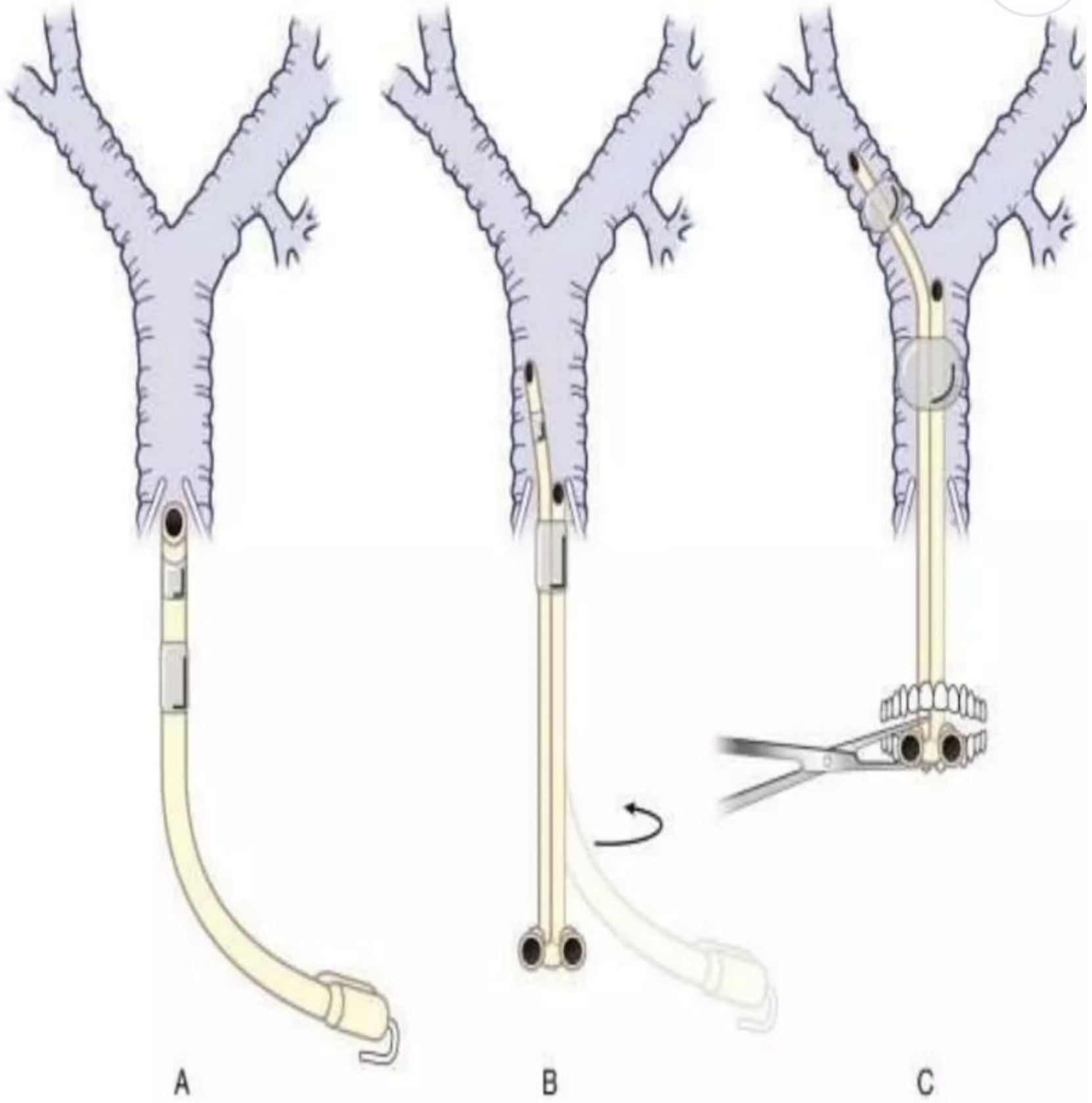

Balloon Tipped Bronchial Blockers

- The blocker is placed within or next to a single lumen endotracheal tube and advanced under direct visualization utilizing fiberoptic bronchoscopy into the mainstem bronchus of the operative lung.
- The cuff is then inflated under direct vision to ensure adequate positioning and seal of the bronchus.



- Single lumen endotracheal tube placed at midtracheal position.
- Blocker placed through multi-port adapter.
- Fiberoptic bronchoscope placed through multiport adapter and advanced.
- Coupled bronchoscope and blocker advanced to the side of the lung to be blocked
- Once in mainstem bronchus, bronchoscope is withdrawn and the cuff inflated under direct vision
- Fiberoptic bronchoscope removed entirely.

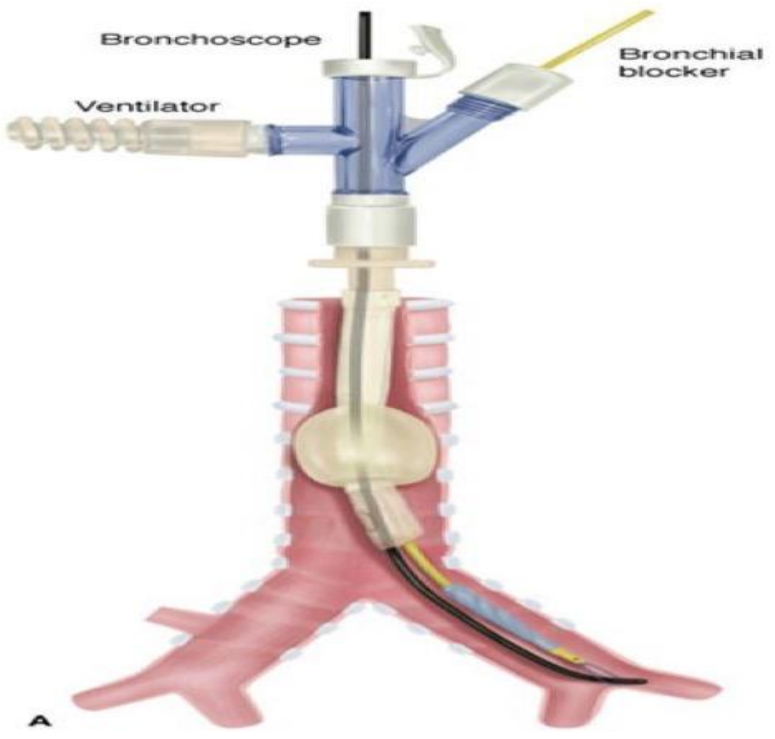
Bronchoscope
Bronchial blocker
Ventilator
A

	ADVANTAGES	DISADVANTAGES
DLET	• Can suction lungs independently • Quality of suctioning better • Can apply CPAP to non-ventilated lung more easily	• Difficult to insert in distorted airway • Needs change in postoperative ventilation • Needs determination of appropriate size • Potential for tracheo-bronchial injury
Bronchial Blockers	• Can be used for selective lobar blockade • in tracheostomized patients • in critically ill patients already intubated with a single-lumen tube • Can be used in children and small adults	• lung inflates and deflates very slowly • difficult to apply CPAP to non-dependent lung
Endobronchial intubation	• Useful in emergencies massive bleeding • Useful in children and very small adults	• Inability to ventilate or suction opposite lung If on right side • high risk of obstructing right upper lobe bronchus

One-lung ventilation (OLV)

- It refers to mechanical separation of the lungs to allow ventilation of only one lung.
- It is done to facilitate surgical exposure for thoracic surgeries
- It may be used to isolate a pathologic lung from a healthy one to prevent soiling or to provide differential ventilation.

Lung Physiology:

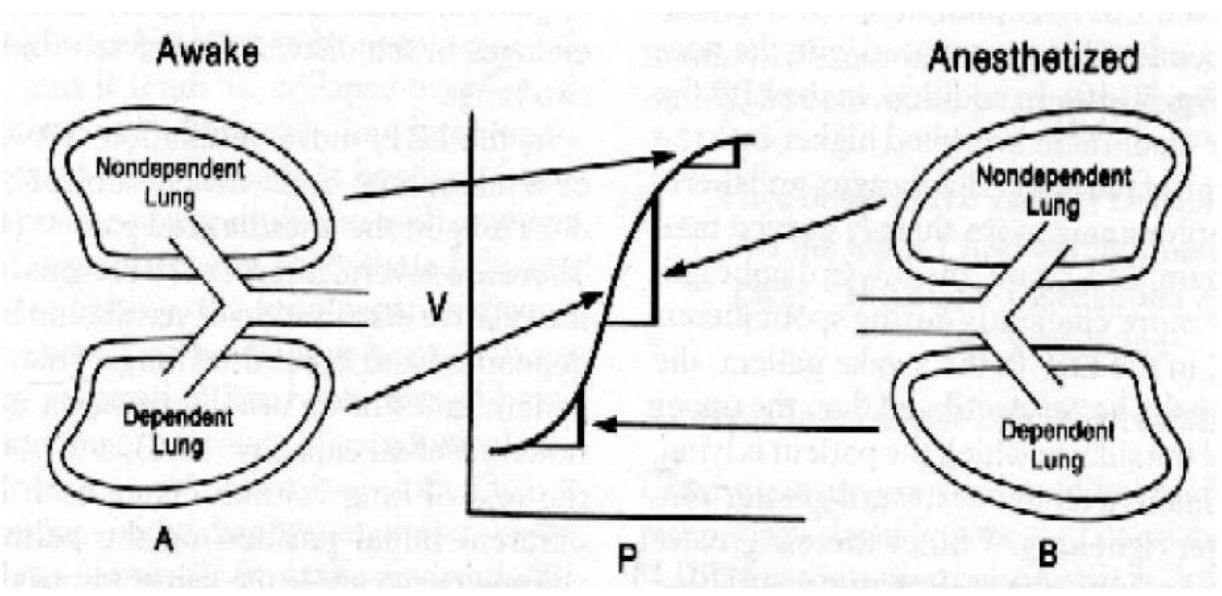
Awake
Anesthetized
Nondependent Lung
Dependent Lung
V
Nondependent Lung
Dependent Lung
A
P
B

When a patient is awake-

- The **dependent part** OF LUNG gets more blood supply and better perfused due to gravity.

The Dependent part→better ventilated due to being slightly more compressed than the non-dependent lung so greater compliance once atelectatic airways at the base have opened

- **Non-dependent lung**- less blood supply and less ventilation.

So, **in awake patients V/Q is well maintained, and shunt fraction is 1-2 %.**

During Anesthesia

- Paralysis of the diaphragm and intercostal muscles leads to decreased FRC.
- The mediastinal weight becomes unsupported as it is relaxed.

Because of both these changes lung physiology alters.

- Under anesthesia, the **dependent part** shifts to lower on the compliance curve, so ventilation decreases, and the **non-dependent part** shifts to the favorable portion (steeper) on the curve so the ventilation increases.
- **Ventilation scenarios change but perfusion remains the same in parts this increases the V/Q mismatch**.

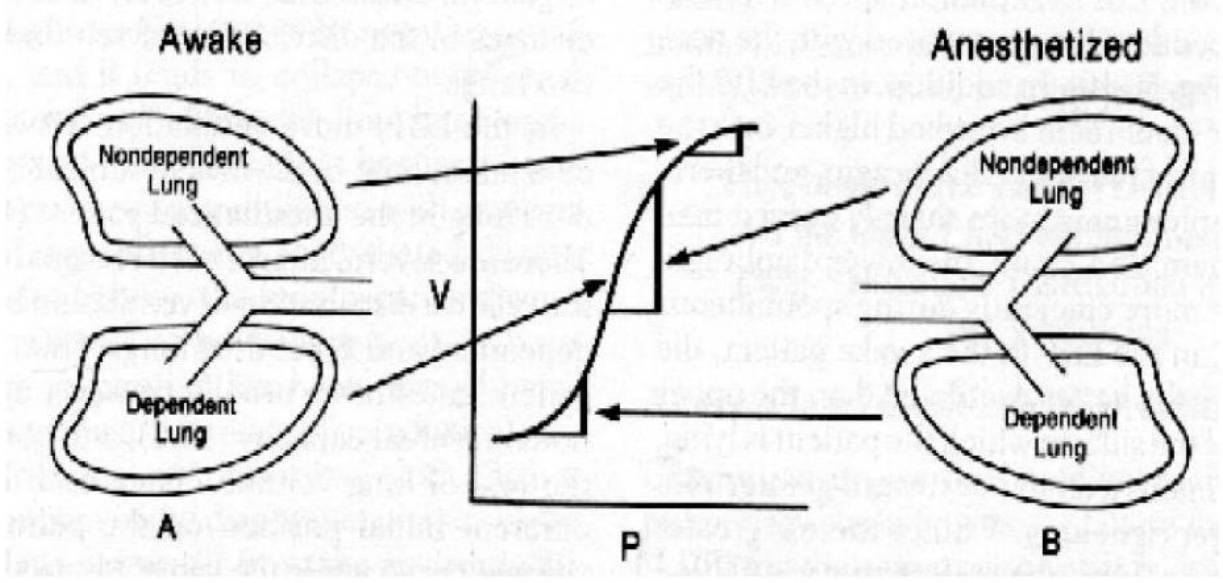
Awake
Anesthetized
Nondependent Lung
Dependent Lung
V
P
Nondependent Lung
Dependent Lung
A
B

Hypoxic pulmonary vasoconstriction

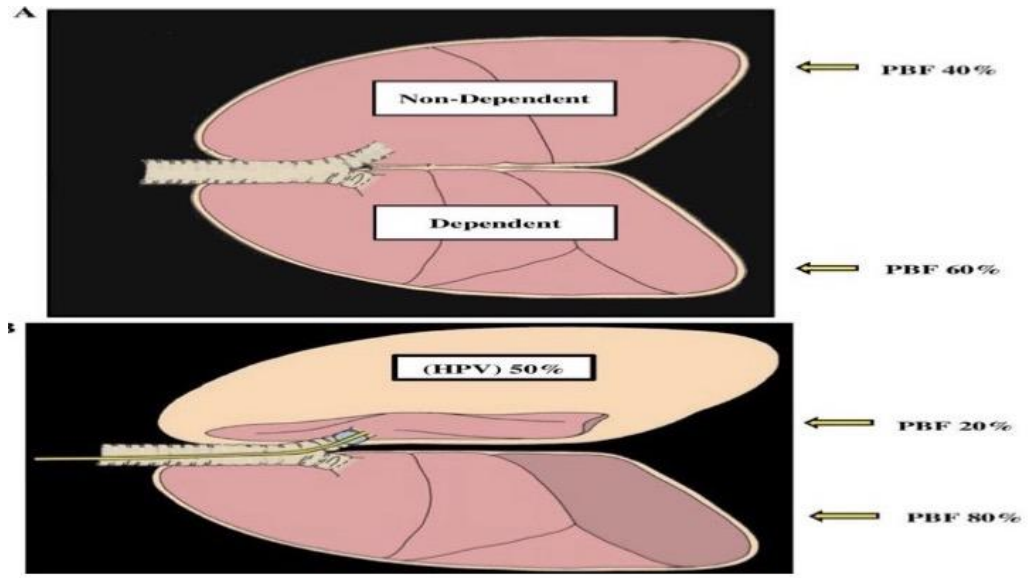

- **Autoregulatory mechanism**
    - **Decreases** the blood flow to the non ventilated lung by about 50%.
    - Alveolar hypoxia triggers the **pulmonary vessels to constrict**→directing blood **away** from poorly/non ventilated areas to better-ventilated segments→ **improving ventilation/perfusion matching.**
    - Rapid onset over the first 30 minutes and then a slower increase to a maximal response at approximately 2 hours.
    - When oxygenation and ventilation are re-established, the attenuation of HPV follows a reverse two-phase pattern

HPV is potentiated (causing less shunt, improving oxygenation)

- Metabolic and respiratory acidosis
- Hypercapnia
- Mild decreased mixed venous oxygenation
- Hyperthermia

HPV is decreased (causing increased shunt, worsening oxygenation)

- Metabolic and respiratory alkalosis
- Hypocapnia
- Hypothermia
- Administration of a volatile inhalation anesthetic at a dose >1 MAC
- Hemodilution

INDICATIONS of OLV

- Pulmonary resection→ pneumonectomy, lobectomy, and wedge resection
- Video-assisted thoracoscopic surgery→ wedge resection, biopsy
- Mediastinal surgery
- Esophageal surgery
- Thoracic vascular surgery
- Thoracic spine surgery
- Minimally invasive cardiac valve surgery

LUNG ISOLATION

- Pulmonary haemorrhage
- Purulent pulmonary secretions
- Bronchopulmonary lavage

Approach to One-Lung Ventilation Management

- FiO2 of 1.0 to denitrogenation
- Tidal Volume of **4-6 mL/kg** with **PEEP 5 cm H20**
- Respiratory rate to maintain End tidal Co2
- Check the DLT/endobronchial blocker position subsequent to the lateral decubitus positioning
- Low airway pressures below 30 cm of H2O.
- Avoid fluid overload
- **TIVA** may be preferable to inhalation anesthetics (Inhalation at 1 MAC blunts HPV so keep MAC below 1 MAC.)

TREATMENT OF HYPOXAEMIA DURING OLV:

- Ensure FiO2 = 1.0
- Check DLT/BB placement with fiberoptic bronchoscopy
- Suction airway
- Optimize cardiac output
- Recruit ventilated lung
- Apply PEEP 5 cm to ventilated lung (except COPD)
- Apply CPAP 5 to 10 cm non-ventilated lung
- Intermittently ventilate both lungs
- Mechanical restriction of pulmonary blood flow to non-ventilated lung

Positioning

- **Lateral decubitus position**
- Common problems are:

1. Ischemia, nerve damage, or compartment syndrome to the dependent arm

2. Postoperative shoulder discomfort

3. Lateral angulation of the neck leading to jugular venous obstruction

4. Hyperextension of the non-dependent arm leading to traction or compression of the brachial and axillary neurovascular bundles.

Regional Anaesthesia:

- **Thoracic Epidural Analgesia**-Bilateral, segmental analgesia can provide effective pain relief.

  Supports coughing, deep breathing and thus secretions removal

  Limitations: hypotension, urinary retention, motor block and rare neuraxial complications.

- **Thoracic Paravertebral Block**-Local anaesthetic is deposited beside the thoracic vertebral bodies, near spinal nerves.

  Usually provides unilateral, segmental chest-wall analgesia.

- **Erector spinae plane (ESP) block**→Local anaesthetic is injected deep to the erector spinae muscle.
- **Serratus anterior plane (SAP) block**→Targets lateral cutaneous branches of intercostal nerves.Useful mainly for lateral chest-wall analgesia.
- **Intercostal nerve block**→Local anaesthetic is injected near the intercostal nerves.
- **Cryoanalgesia**→Controlled freezing temporarily interrupts intercostal nerve conduction.

Postoperative Analgesia

- Multimodal Analgesia
  - Opioids
  - Paracetamol
  - Nonsteroidal Anti-inflammatory Drugs
  - Ketamine
  - Dexmedetomidine
  - Regional Anaesthesia

Postoperative complications

- Bleeding
- Respiratory Complications- Atelectasis ,
- Pneumothorax, post resection hypoxemia
- acute lung injury, air leak
- Injury to surrounding structures- Recurrent Laryngeal Nerve & Phrenic Nerve
- infections

THANK YOU